

# The Novel Design of Zirconium Oxide–Based Screw-Retained Restorations, Maximizing Exposure of Zirconia to Soft Peri-implant Tissues: Clinical Report After 3 Years of Follow-up



Tomas Linkevicius, DDS, Dip Pros, PhD<sup>1</sup>

*Current use of zirconium oxide (ZrO<sub>2</sub>)-based screw-retained restorations does not guarantee maximum contact of soft peri-implant tissues with ZrO<sub>2</sub>, because veneering porcelain usually covers the major subgingival part of the restoration. Ceramics preclude direct interaction between zirconia and soft tissue cells, thus reducing biocompatibility and benefit to the patient. The four case reports discussed in this article describe the new design modality of the ZrO<sub>2</sub> screw-retained restorations, in which zirconia is exposed to the tissues and no veneering porcelain is located below the gingival margin. The article also shows the impact of this treatment on soft peri-implant tissues after 3 years of follow-up. Soft tissue recession, vestibular contour, bleeding on probing, and probing depth were evaluated. Int J Periodontics Restorative Dent 2017;37:41–47. doi: 10.11607/prd.2887*

Due to their easy retrievability and absence of cement remnants, screw-retained implant restorations are preferred by clinicians. Retrievability ensures quick and effective solution of technical complications, while the absence of excess cement allows more favorable response of peri-implant tissues.<sup>1</sup> It has been shown that undetected cement remnants might lead to early and delayed peri-implantitis.<sup>2,3</sup> The American Academy of Periodontology has recognized excess cement as a risk factor in development of peri-implant diseases; therefore, luting remnants should be avoided at any cost.<sup>4</sup>

Currently, a variety of materials may be used for the fabrication of screw-retained restorations, such as metal ceramics, titanium acrylics/composites, or zirconia-based reconstructions. Zirconium oxide (ZrO<sub>2</sub>) offers substantial advantages, including lower adhesion of bacteria,<sup>5</sup> less plaque accumulation,<sup>6</sup> better proliferation of fibroblasts,<sup>7</sup> and as a recent clinical study indicates, even reduced probing depths.<sup>8</sup> Its superior biocompatibility stimulates increased prescription by clinicians and acceptance by patients. Since zirconia is used for implant abutments without restrictions,<sup>9</sup> this material could be suggested for fabrication of screw-retained restorations as well.

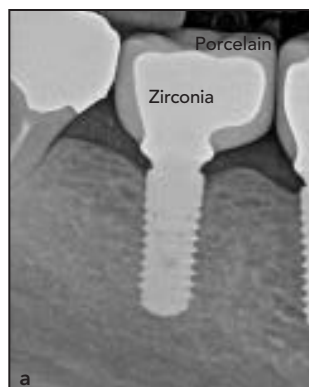<sup>1</sup>Associate Professor, Institute of Odontology, Faculty of Medicine, Vilnius University, Vilnius Mokslo Grupe, Vilnius, Lithuania; Vilnius Implantology Center, Vilnius, Lithuania.

Correspondence to: Dr Tomas Linkevicius, Institute of Odontology, Faculty of Medicine, Vilnius University, Zalgirio str 115/117, LT-08217, Vilnius, Lithuania. Fax: +370 5 276 0725. Email: linktomo@gmail.com

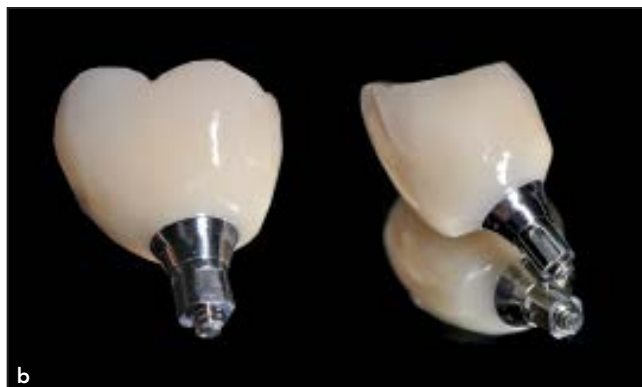©2017 by Quintessence Publishing Co Inc.



**Fig 1** Schematic drawing of standard  $ZrO_2$  screw-retained restoration, where the veneering porcelain is blocking the zirconia from contact with peri-implant tissues.



**Fig 2**  $ZrO_2$  without  $ZrO_2$  restoration. (a) Radiographic image. Ceramics are clearly located below the gingival line. (b) Clinical view. A line of zirconia is barely visible near the connection with the titanium base.



The production of screw-retained restorations follows a specific protocol. One common step is covering the entire framework with veneering ceramic to the most apical part of the crown (Fig 1). Screw retention of the finished restoration on the implant positions the veneering porcelain under the peri-implant mucosa (Fig 2a). If the traditional protocol is followed, the zirconia framework is blocked from the tissues by veneering porcelain. The reconstruction is called “ $ZrO_2$  without  $ZrO_2$ ” when no direct or only minimal contact between  $ZrO_2$  and soft tissues is achieved (Fig 2b). Patients treated with these restorations do not receive the benefits of zirconia, as the peri-implant tissues primarily have contact with dental porcelain, which is much less biocompatible. The rationale for masking zirconia with feldspathic ceramics may be based on the notion that  $ZrO_2$  can age and subsequently weaken when confronted with the oral environment.<sup>10</sup> Veneering porcelain

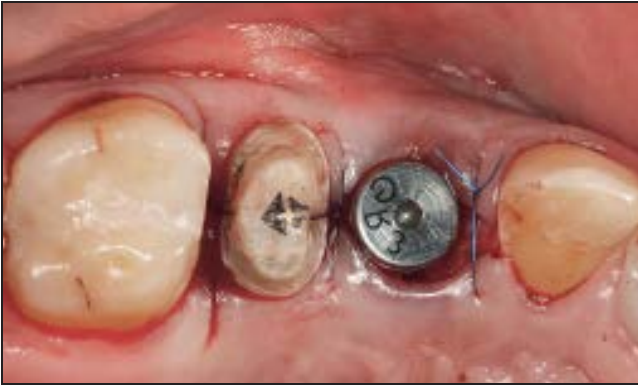protects  $ZrO_2$  from contact with saliva and precludes weakening of the material. However, recent studies do not confirm the idea that saliva can make  $ZrO_2$  weaker with time.<sup>11</sup> Therefore, it can be speculated that if a screw-retained  $ZrO_2$  restoration is designed in the traditional way, no difference in peri-implant soft tissue response will occur compared with metal-ceramic restorations since the biologic properties of the veneering porcelain used for zirconia and metal are the same. This article describes a novel design for a  $ZrO_2$ -based screw-retained implant restoration that allows the maximum contact of peri-implant tissues with zirconia and shows the impact of the design on soft peri-implant tissues after 3 years of follow-up.

#### Clinical report

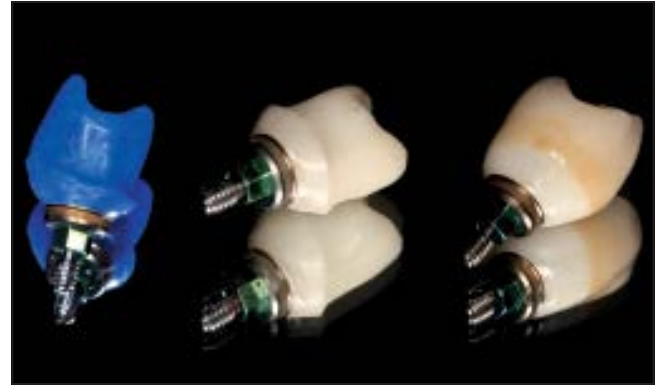
A healthy 24-year-old patient had a 4.6-mm-diameter tapered two-piece implant (Tapered Laser-Lok,

BioHorizons) immediately placed in the maxillary premolar region (Fig 3). After 3 months and successful osseointegration, the decision was made to restore the implant with a  $ZrO_2$ -based screw-retained restoration designed using a novel technique. As the implant was placed at a moderate depth (3-mm healing abutment), no provisional restoration to form the soft tissues was considered. An open-tray impression was taken with polyvinyl siloxane (Variotime, Heraeus Kulzer) and the implant position and peri-implant architecture were transferred to the master cast.

The cast around the implant analog was trimmed to form an emergence profile for the future restoration.  $ZrO_2$  framework was waxed on a 4.5-mm titanium base (Laser-Lok Titanium Base Abutment, BioHorizons). The shape was scanned and milled from zirconia (Fig 4). The scaffold of such a restoration can be divided into two areas: (1) the peri-implant tissue area with pure  $ZrO_2$ ,

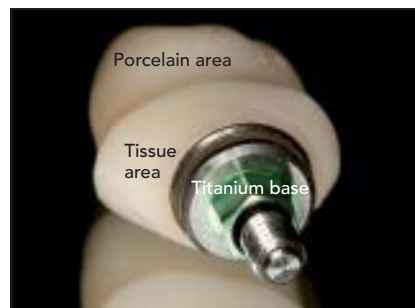

**Fig 3** Immediate placement of the implant in the first premolar site.

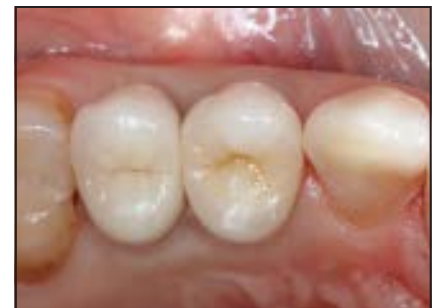

**Fig 4** Wax framework (left),  $ZrO_2$  framework (center), and finished restorations (right). Note the clear margin on the finished restoration between  $ZrO_2$  and veneering porcelain.

and (2) the ceramic area, where only porcelain is applied (Fig 5). It is designed in such a way that veneering ceramics start at the emergence point of the restoration from peri-implant tissues and do not go into the subgingival area. Subsequently, feldspathic porcelain (VITA VM9, Vita Zahnfabrik) was layered on  $ZrO_2$  without touching the soft tissue part of the framework. Zirconia on the soft tissue part was polished at a low speed with silicone polishers until visibly smooth under the microscope and to the naked eye. After glazing, the restoration was luted onto the titanium base with resin cement (Multilink Hybrid Abutment, Ivoclar Vivadent) and the cement remnants were removed with a sharp scalpel (Fig 4). In the clinic, the restoration underwent an ultrasonic cleaning procedure with ethyl alcohol and antibacterial solution for 10 minutes, as proposed by Canullo et al.<sup>12</sup> After disinfection, the restoration was attached to the implant, causing slight compression and



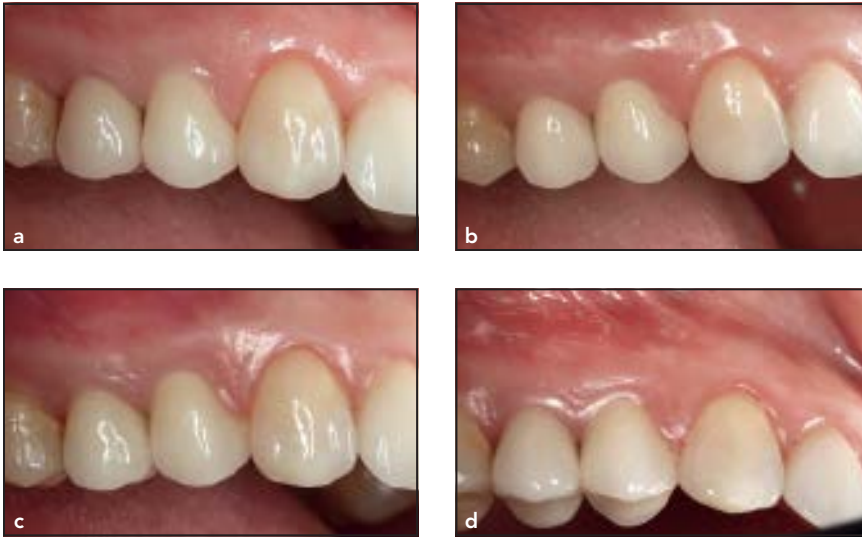**Fig 5** Schematic showing areas for soft tissue contact and veneering porcelain.



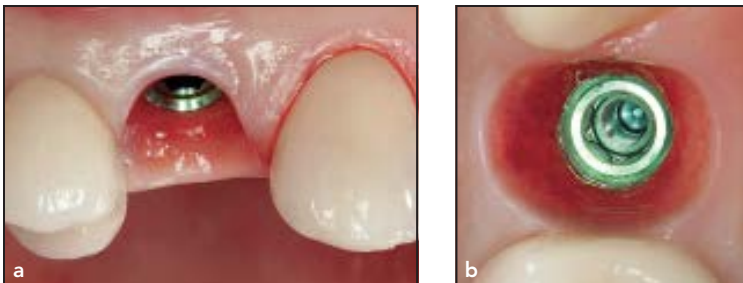
**Fig 6** Covering the access hole with composite for a first premolar implant restoration. Tissues still show some compression signs from blanching.

blanching of the tissues, which had disappeared after approximately 15 minutes. The occlusal opening was closed with a light-cured resin composite (Gradia Anterior, GC) (Fig 6). After 3 years' post-treatment recall, the contour of the tissues above the restoration was convex and did not differ from that of the neighboring premolar. Peri-implant soft tissues appeared healthy and in durable

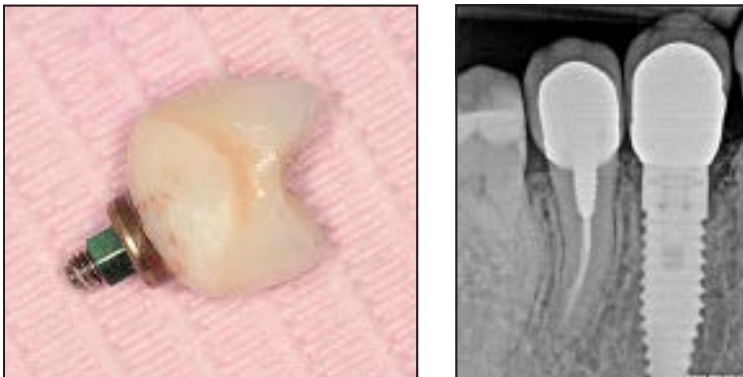
contact with zirconia underneath. No recession was recorded (Fig 7). An air-blow test, in which the margin of the crown is challenged with compressed air, showed no visually detectable detachment of the peri-implant mucosa from the restoration. No bleeding on probing was recorded, and probing depths did not exceed accepted references. To inspect soft tissues more closely



**Fig 7** Soft tissue condition at delivery (a), 1-year (b), and 3-year follow-up (c and d). Note the firmness and stability of the soft tissues over the  $ZrO_2$  screw-retained restoration on the first premolar, in comparison with the soft tissue condition at delivery.



**Fig 8** Peri-implant soft tissues after 3 years in contact with  $ZrO_2$  without coverage with veneering porcelain.



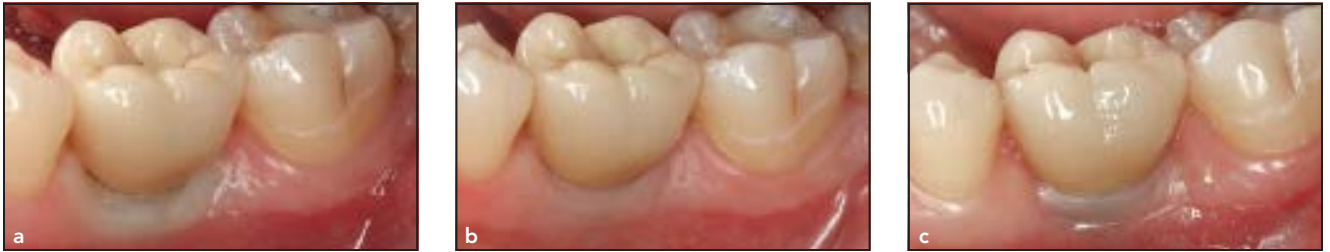**Fig 9** (left) Removed screw-retained restoration. Some blood is present on the  $ZrO_2$ , indicating possible disruption of hemidesmosomal attachment

**Fig 10** (right) Radiographic image of the restoration. Note that the zirconia is not covered with porcelain in the subgingival area.

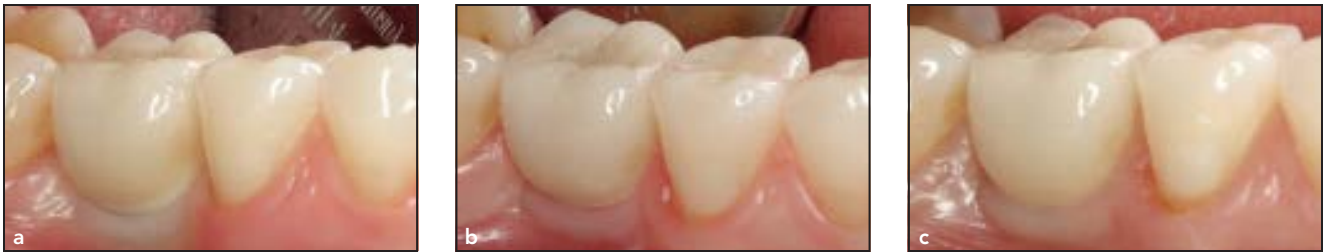and clean the implant inside, the restoration was unscrewed. The removal caused bleeding of the soft peri-implant tissues, possibly indicating hemidesmosomal attachment to

the zirconia surface (Figs 8 and 9). After inspection, the restoration was secured back to the implant. Radiographic examination revealed stable crestal bone levels (Fig 10).

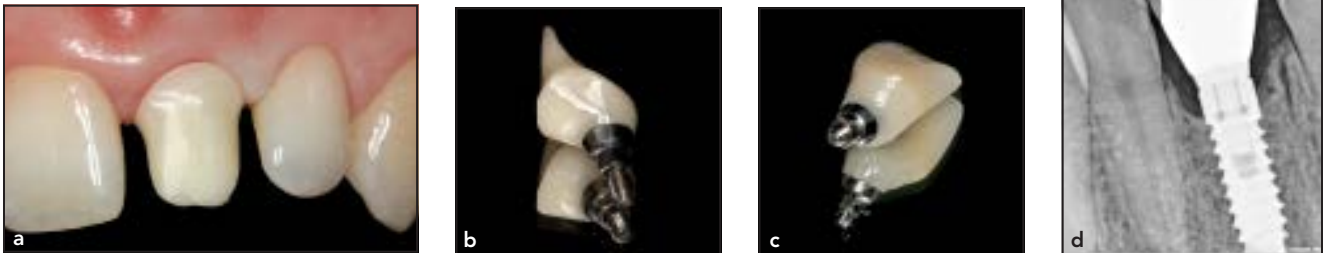
Similar visual adhesion of the peri-implant soft tissues to the underlying  $ZrO_2$  and stable situation was also recorded in other cases (Figs 11 to 14).



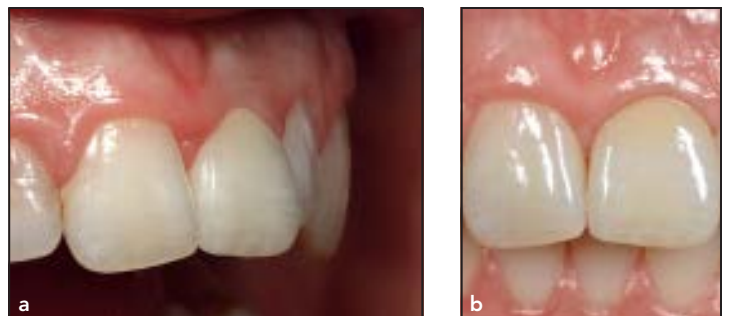**Fig 11** Clinical outcome of novel design  $ZrO_2$ -based screw-retained restorations. (a) Delivery. (b) 1-year follow-up. (c) 3-year follow-up. Note the stability of peri-implant soft tissues after 3 years.



**Fig 12** Clinical outcome of novel design  $ZrO_2$ -based screw-retained restorations. (a) Delivery. (b) 1-year follow-up. (c) 3-year follow-up. Note the stability of peri-implant soft tissues after 3 years.



**Fig 13** (a, b) Framework of  $ZrO_2$  screw-retained restoration. Note the line for veneering porcelain just at the margin of peri-implant sulcus. (c) Finished restoration with clearly visible color differences between polished  $ZrO_2$  and porcelain. (d) Radiographic image of the restoration. Note that the  $ZrO_2$  is not covered with porcelain in the subgingival area.



**Fig 14** Clinical views at 1 year (a) and 3 years (b) showing excellent soft tissues stability and texture.

## Discussion

One of the major reasons patients and clinicians choose zirconia as prosthetic material for implant restorations is its biocompatibility. However, the traditional design of screw-retained restorations usually precludes the contact of  $ZrO_2$  with peri-implant tissues, as the zirconia is covered with veneering ceramics even subgingivally. This greatly reduces the positive impact of  $ZrO_2$ , and puts soft tissues in contact with feldspathic porcelain, which is a common veneering material for  $ZrO_2$  frameworks. Dental porcelain has been shown not to be a proper material for the establishment of reliable soft tissue adherence. In the same study, the outcome with feldspathic ceramics was shown to be least favorable, with the greatest soft tissue recession and bone loss among the tested materials.<sup>13</sup> This approach is probably inherited from the fabrication of metal-ceramic reconstructions, when application of veneering porcelain was a must to cover the metallic color of the framework. Another explanation is avoiding exposure of  $ZrO_2$  to the oral environment, as this may cause aging of the material and subsequent weakening. However, recent research has shown that the strength of zirconia is not significantly reduced by saliva.<sup>11</sup> In addition, there is no logic to support covering subgingival parts of screw-retained restoration with ceramics, considering that zirconia abutments for cemented-retained restorations are never covered with porcelain. New design approaches aim at maximiz-

ing the exposure of  $ZrO_2$  to peri-implant tissues. The basic idea is to design restorations so that there is a strict demarcation line between pure  $ZrO_2$  and dental porcelain. That is possible using the technique described here.

One of the major benefits of zirconia is its ability to be smoothly polished. A recent *in vitro* study has shown that the roughness of the material is very important in the behavior of cells on  $ZrO_2$  or titanium oxide ( $TiO_2$ ). It was found that polished  $ZrO_2$  surfaces provided better adhesion for epithelial cells when compared with  $TiO_2$ .<sup>7</sup> In addition, van Brakel et al have shown significantly reduced probing depths around polished  $ZrO_2$  abutments compared with titanium parts in 20 patients.<sup>8</sup> These results might be explained by better adhesion of epithelial cells to a polished  $ZrO_2$  surface. In addition, studies report reduced bacteria accumulation and lower inflammation levels around zirconia.<sup>5,6</sup> It can be speculated that a less inflammatory environment could lead to a tighter and more rigid peri-implant sulcus. In contrast, Bollen et al<sup>14</sup> showed no significant difference in probing depths between polished  $ZrO_2$  and  $TiO_2$  abutments. Furthermore, increased bleeding on probing was recorded around ultrapolished  $ZrO_2$  abutments. However, because this study involved only six patients, no final conclusions could be drawn. It remains unclear what level of polished  $ZrO_2$  should be exposed to peri-implant tissues to receive the most positive effects of cell adhesion.

On the other hand, case reports in general do not provide strong clinical evidence.<sup>15</sup> Clinical reports may serve as pilot observations, which could lead to well-designed controlled clinical trials. Future clinical studies, which would show the reaction of peri-implant soft tissues to zirconia abutments of different polishing scales, or compare zirconia to zirconia covered with porcelain, would be necessary to fully answer the question.

## Conclusions

Within the inherent limitations of this case report, it could be suggested that the novel design for  $Zr_2O$  screw-retained restorations in which zirconia is maximally exposed to peri-implant tissues offers significant advantages compared with implant-supported crowns in which subgingival parts are covered with veneering porcelain. The benefits of biocompatibility can be obtained only if the soft tissues have direct contact with the zirconia. Therefore, it can be suggested that the biologic advantage of the traditional design for  $ZrO_2$  screw-retained restorations is limited.

The clinical cases presented exemplify technical and clinical steps of implementing the novel design restorations into everyday clinical practice. A 3-year follow-up showed good clinical outcomes and stable crestal bone levels.

## Acknowledgments

The author would like to thank Mr Rolandas Andrijauskas, CDT from DTL Vilnius Lab for his laboratory support and input in preparing this manuscript. The author reported no conflicts of interest related to this study.

## References

1. Sailer I, Mühlemann S, Zwahlen M, Hammerle CH, Schneider D. Cemented and screw-retained implant reconstructions: A systematic review of the survival and complication rates. *Clin Oral Implants Res* 2012;23(suppl):163–201.
2. Wilson TG Jr. The positive relationship between excess cement and peri-implant disease: A prospective clinical endoscopic study. *J Periodontol* 2009;80:1388–1392.
3. Linkevicius T, Puisys A, Vindasiute E, Linkeviciene L, Apse P. Does residual cement around implant-supported restorations cause peri-implant disease? A retrospective case analysis. *Clin Oral Implants Res* 2013;24:1179–1184.
4. Peri-implant mucositis and peri-implantitis: A current understanding of their diagnoses and clinical implications. *J Periodontol* 2013;84:436–443.
5. Degidi M, Artese L, Scarano A, Perrotti V, Gehrke P, Piattelli A. Inflammatory infiltrate, microvessel density, nitric oxide synthase expression, vascular endothelial growth factor expression, and proliferative activity in peri-implant soft tissues around titanium and zirconium oxide healing caps. *J Periodontol* 2006;77:73–80.
6. Scarano A, Piattelli M, Caputi S, Favero GA, Piattelli A. Bacterial adhesion on commercially pure titanium and zirconium oxide disks: An in vivo human study. *J Periodontol* 2004;75:292–296.
7. Nothdurft FP, Fontana D, Ruppenthal S, et al. Differential behavior of fibroblasts and epithelial cells on structured implant abutment materials: A comparison of materials and surface topographies. *Clin Implant Dent Relat Res* 2015;17:1237–1249.
8. van Brakel R, Cune MS, van Winkelhoff AJ, de Putter C, Verhoeven JW, van der Reijden W. Early bacterial colonization and soft tissue health around zirconia and titanium abutments: An in vivo study in man. *Clin Oral Implants Res* 2011;22:571–577.
9. Zembic A, Philipp AO, Hammerle CH, Eohlwend A, Sailer I. Eleven-year follow-up of a prospective study of zirconia implant abutments supporting single all-ceramic crowns in anterior and premolar regions. *Clin Implant Dent Relat Res* 2015;17:e417–e426.
10. Ban S, Sato H, Suehiro Y, Nakanishi H, Nawa M. Biaxial flexure strength and low temperature degradation of Ce-TZP/Al<sub>2</sub>O<sub>3</sub> nanocomposite and Y-TZP dental restoratives. *J Biomed Mater Res B Appl Biomater* 2008;87:492–498.
11. Harada K, Shinya A, Gomi H, Hatano Y, Shinya A, Raigrodski AJ. Effect of accelerated aging on the fracture toughness of zirconias. *J Prosthet Dent* 2016;115:215–223.
12. Canullo L, Micarelli C, Lembo-Fazio L, Iannello G, Clementini M. Microscopical and microbiologic characterization of customized titanium abutments after different cleaning procedures. *Clin Oral Implants Res* 2014;25:328–336.
13. Abrahamsson I, Berglundh T, Glantz PO, Lindhe J. The mucosal attachment at different abutments. An experimental study in dogs. *J Clin Periodontol* 1998;25:721–727.
14. Bollen CM, Papaioanno W, van Eldere J, Schepers E, Quirynen M, van Steenberghe D. The influence of abutment surface roughness on plaque accumulation and peri-implant mucositis. *Clin Oral Implants Res* 1996;7:201–211.
15. Richards D. Not all evidence is created equal – so what is good evidence? *Evid Based Dent* 2003;4:17–18.

## Erratum

In the article by Laurito et al (Socket Preservation with d-PTFE Membrane: Histologic Analysis of the Newly Formed Matrix at Membrane Removal), in Volume 36, Number 6 (November/December), 2016, the first author's first name is spelled incorrectly. The correct full name is Domenica Laurito, DDS, PhD.

Copyright of International Journal of Periodontics & Restorative Dentistry is the property of Quintessence Publishing Company Inc. and its content may not be copied or emailed to multiple sites or posted to a listserv without the copyright holder's express written permission. However, users may print, download, or email articles for individual use.